

HISTOPATHOLOGICAL OBSERVATIONS ON LUNGS OF BALB/C MICE EXPERIMENTALLY INFECTED WITH HUMAN METAPNEUMOVIRUS AND HUMAN RESPIRATORY SYNCYTIAL VIRUS



Ali Hussain Hassan *, Tariq A. G. Aziz ** and
Ali Hattem Bayati ***

Submitted 6th September 2015; accepted 10th January 2016

ABSTRACT

Background

Human respiratory syncytial virus (HRSV) and human metapneumovirus (HMPV) are responsible for a high percentage of pediatric medical admissions and considered major causes of morbidity and mortality among children in developing countries.

Objective

To investigate histopathological findings in lungs of BALB/c mice exposed to intranasal inoculation with human respiratory syncytial virus and human metapneumovirus.

Materials and Methods

Thirty six BALB/c mice were divided into 4 groups (9 mice/group) as follows, Group 1 mice inoculated by viral transport medium (VTM) treated with nasopharyngeal swabs (NPS) obtained from children positive for HRSV; group 2 mice inoculated by VTM treated with NPS obtained from children positive for the HMPV; group 3 mice inoculated by sterile VTM and group 4 mice were free of inoculation. The mice were sacrificed using inhalation anesthesia and their lungs were excised and undergone histopathological processes to prepare tissue sections for microscopic examination.

Results

Frequency rates of NPS positive for HMPV and HRSV were relatively high but they coincide with the reported incidences of HMPV and HRSV infections among children worldwide. An intense inflammatory response was observed in HRSV-inoculated mice represented mainly by infiltration of mononuclear inflammatory cells in the perivascular and peribronchiolar areas associated with alveolar distortion and bronchiolar epithelial sloughing and also associated with syncytium formation within the epithelial tissue in two mice. On the other hand, HMPV-inoculated mice showed a less intense mononuclear inflammatory response in the perivascular and peribronchiolar areas associated with bronchiolar epithelial sloughing, slight deposition of edematous fluid within the interalveolar septa and distortion of alveolar tissue.

Conclusion

The direct fluorescent assay (DFA) showed high frequency rates of HRSV and HMPV infection among children admitted to the Pediatric Teaching Hospital in Al Sulaimaniyah city and the histopathological examination of the lungs of mice exposed to intranasal inoculation with HRSV revealed an intense mononuclear inflammatory response, alveolar tissue distortion, bronchiolar epithelial sloughing and syncytium formation compared to less intense mononuclear inflammatory response in lungs of HMPV-inoculated mice.

Keywords: *HRSV, HMPV, BALB/c mice.*

* College of Veterinary Medicine, Sulaimani University, Sulaimani, Iraq Kurdistan Region.

Correspondence: ali.hasan@univsul.edu.iq

** School of Medicine, Sulaimani University, Sulaimani, Iraq Kurdistan Region.

*** College of Technical Health, Sulaimani Polytechnic University, Sulaimani, Iraq Kurdistan Region.

INTRODUCTION

Human respiratory syncytial virus and human metapneumovirus are respiratory pathogens belonging to the *Paramyxoviridae* family⁽¹⁾. They are responsible for a high percentage of the pediatric medical admissions due to bronchiolitis and pneumonia^(2,3) and considered as major causes of morbidity, hospitalizations, and mortality among children under 5 years of age in developing countries⁽⁴⁾.

Experimental animals such as the cynomolgus macaques, BALB/c mice and other small rodents are usually used to study the pathogenesis and pathology of HRSV and HMPV infection⁽⁵⁻⁸⁾, hence the current study was conducted to check out the histopathological findings in BALB/c mice experimentally exposed to intranasal inoculation with viral transport medium (VTM) treated with nasopharyngeal swabs (NPS) obtained from children proved to be positive for the HRSV and HMPV in Sulaimani governorate, Iraqi Kurdistan Region.

MATERIAL AND METHODS

Samples

Nasopharyngeal swabs were obtained from 300 children less than 5 years old admitted to the Pediatric Teaching Hospital in Sulaimani city due to respiratory tract problems of undiagnosed etiology from the 1st of December 2014 through the 31st of January 2015. Two NPS were obtained from each child and immersed in a test tube containing VTM, the first one was used for detection of HRSV and HMPV by the direct fluorescent assay and if proved to be positive for either of the two tested viruses, the second NPS swab was used for induction of experimental respiratory infections in BALB/c mice. This study was conducted with the approval of the ethical committee in College of Veterinary Medicine, University of Sulaimani.

Detection of HRSV and HMPV in NPS by the direct fluorescent assay

The direct fluorescent assay (DFA) was used in this study for simultaneous detection of HRSV and HMPV in nasopharyngeal swabs. Briefly, the swab in VTM was vortexed, wrung out and then discarded; the VTM was then centrifuged for 5 min to pellet the cells. The cell pellets were resuspended in a small amount of PBS, concentrated by centrifugation, placed on a slide, air dried and fixed in cold acetone for 10 min. Thereafter,

the slide was stained with 40 µl of SimulFluor HMPV/HRSV reagent (Millipore, Billerica, MA, USA), incubated for 15 min at 37°C., washed in PBS, mounted in glycerol and examined by a fluorescence microscope to detect the presence of rhodamine-labeled cells by the use of a rhodamine filter (in case of HRSV infection) and then re-examined to detect the presence of fluorescein-labeled cells by the use of a fluorescein filter (in case of HMPV infection).

A positive result was indicated by manifestation of two or more intact cells exhibiting specific reaction represented by appearance of red-colored fluorescence for rhodamine-labeled antibodies in case of HRSV infection and bright apple green fluorescence for fluorescein isothiocyanate (FITC)-labeled antibodies in case of HMPV infection.

Experimental infection of BALB/c mice with HRSV and HMPV

Thirty six adult BALB/c mice (*Mus musculus*) of both genders were divided into four groups; group 1 (HRSV group) included 9 mice inoculated intranasally by VTM treated with nasopharyngeal swabs proved to be positive for HRSV by the DFA test (two drops of VTM approximately equal to 50 µl in each nostril); group 2 (HMPV group) included 9 mice similarly inoculated by VTM treated with nasopharyngeal swabs proved to be positive for HMPV by the DFA test; group 3 (VTM control group) included 9 mice inoculated intranasally by sterile VTM and group 4 (non-inoculated control group) included 9 mice which were free of inoculation. Thereafter, the total nine mice in each group were sacrificed using inhalation anesthesia (halothane) on days 4, 7 and 10 after starting of the experiment (3 mice/day).

Histopathological Examination

The lungs of the sacrificed mice were excised, cleaned by normal saline, fixed in 10% neutral buffered formalin for 24 hours and undergone a series of histopathological processes to prepare 5-6 micrometer thick tissue sections which were fixed on glass slides, stained by hematoxylin and eosin dyes and examined by different magnifying powers of the light microscopy.

RESULTS

Detection of HRSV and HMPV in nasopharyngeal swabs by the DFA

Out of the total 300 nasopharyngeal swabs involved in the present study, 74 swabs were positive for HRSV (24.7%) and 44 swabs were positive for HMPV (14.7%)

as detected by the DFA which showed specific red-colored fluorescence for rhodamine-labeled antibodies in the cytoplasm of HRSV-infected epithelial cells (Figure 1) and bright green fluorescence for FITC-labeled antibodies in the cytoplasm of HMPV-infected epithelial cells (Figure 2).

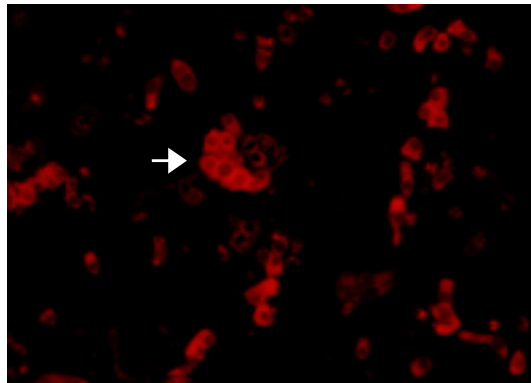


Figure 1. Immunofluorescence microscopy image of respiratory epithelial cells “prepared and fixed on slide from a nasopharyngeal swabs involved in the present study” stained by the SimulFluor HMPV/HRSV reagent. The cells were examined for detection of HRSV by the use of a rhodamine filter. Specific red-colored fluorescence (white arrow) for rhodamine-labeled antibodies is apparent in the cytoplasm of HRSV-infected cells.

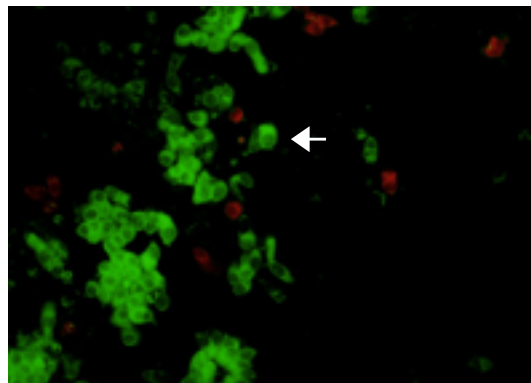


Figure 2. Immunofluorescence microscopy image of respiratory epithelial cells “prepared and fixed on slide from a nasopharyngeal swab involved in the present study” stained by the SimulFluor HMPV/HRSV reagent. The cells were examined for detection of HMPV by the use of a fluorescein filter. Specific green-colored fluorescence (white arrow) for FITC-labeled antibodies is apparent in the cytoplasm of HMPV-infected cells.

Histopathological findings

Histopathological findings of HRSV group (group 1)

One of the mice in group 1 “exposed to intranasal inoculation with HRSV-treated VTM” died at the fourth post-inoculation day and the tissue sections of its lungs showed an intense perivascular and peribronchiolar infiltration with mononuclear inflammatory cells (macrophages and lymphocytes); the inflammatory cells infiltration was extended into the bronchiolar wall with prominent distortion of the alveolar tissue in the adjacent areas (figure 3). The other two mice that were sacrificed at the fourth day in this group showed relatively less intense mononuclear inflammatory cells infiltrate which was also extending into the walls of bronchioles.

At the seventh post-inoculation day, the lungs of the sacrificed mice showed less intense inflammatory reaction with predominance of macrophages and lymphocytes associated with alveolar tissue distortion and bronchiolar epithelial sloughing (figure 4). In addition, the lung sections of two of these mice showed syncytium formation within the epithelial pulmonary tissue (figure 5).

The inflammatory reaction was markedly reduced by the tenth post-inoculation day, at which the lung sections of the sacrificed mice showed slight infiltration of mononuclear inflammatory cells.

Histopathological findings of HMPV group (group 2)

The lungs tissue sections of group 2 mice “that were inoculated with HMPV-treated VTM” showed a less potent inflammatory response in comparison with that seen in lungs of group 1 mice, characterized by infiltration of mononuclear inflammatory cells within the perivascular and peribronchiolar areas associated with slight edema within the interalveolar septa at the 4th post inoculation day (figure 6). On day 7 post-inoculation, there was a more intense inflammatory response represented by blood vessel congestion, bronchiolar epithelial sloughing, infiltration with mononuclear inflammatory cells and distortion of alveolar tissue (figure 7). By the 10th post-inoculation day, the lung tissue section showed nearly normal tissue with few inflammatory cells without edema in the pulmonary tissue.

Histopathological findings of the control groups (groups 3 and 4)

No significant inflammatory response or obvious abnormalities were observed in lung sections (figure 8) of the control mice (group 3 mice which were inoculated with sterilized VTM and group 4 mice which were free of any inoculation).

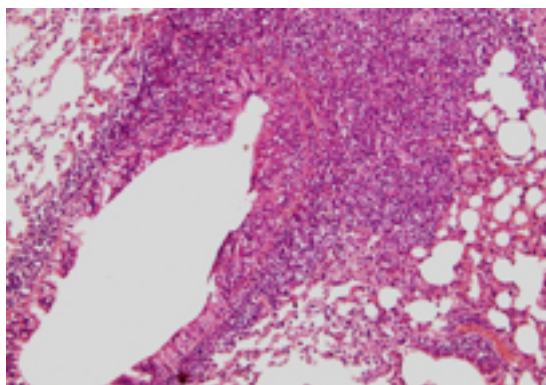


Figure 3. Microscopic view of a lung tissue section obtained from a mouse died 4 days following intranasal inoculation with HRSV-treated VTM (group 1). It shows an intense infiltration with mononuclear inflammatory cells (lymphocytes and macrophages) within the peri-vascular and peri-bronchiolar areas associated with prominent distortion of alveolar tissue. H and E stain, X 100

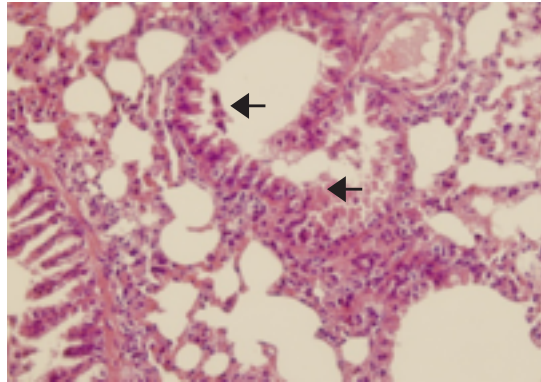


Figure 4 . Microscopic view of a lung tissue section taken from a mouse sacrificed 7 days following intranasal inoculation with HRSV-treated VTM (group 1). The inflammatory infiltrate is markedly reduced; however, the alveolar tissue distortion is still apparent. In addition, bronchiolar epithelial sloughing is also evident (arrows). H and E stain, X 200.

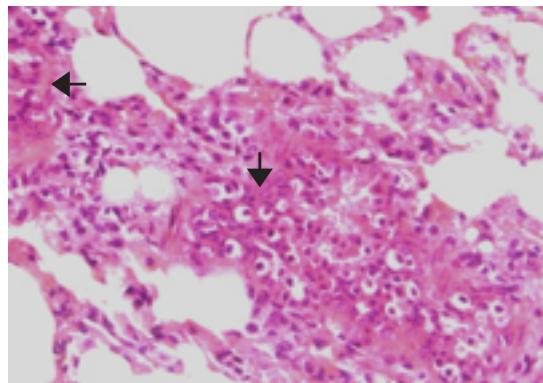


Figure 5. Microscopic view of a lung tissue section obtained from a mouse sacrificed on day 7 following intranasal inoculation with HRSV-treated VTM (group 1). It shows syncytium formation due to fusion of epithelial cells within the pulmonary tissue (black arrows). H and E stain, X 200.

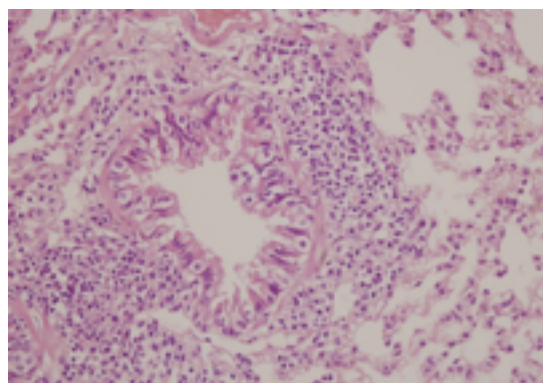


Figure 6. Lung tissue section obtained from a mouse sacrificed on day 4 following intranasal inoculation with HMPV-treated VTM (group 2). It shows infiltration with mononuclear inflammatory cells within the peribronchiolar areas associated with slight edema within the interalveolar septa. H and E stain, X 200.

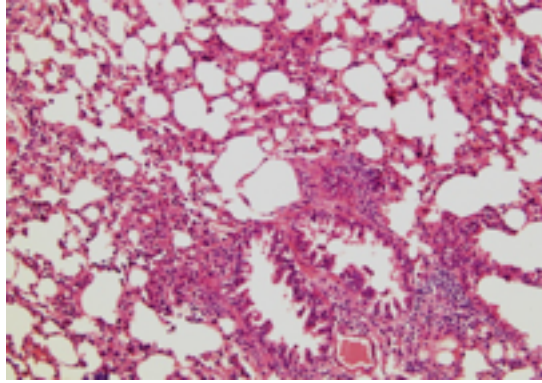


Figure 7. Lung tissue section obtained from a mouse sacrificed on day 7 following intranasal inoculation with HMPV-treated VTM (group 2). It shows blood vessel congestion, bronchiolar epithelial sloughing, infiltration with mononuclear inflammatory cells and distortion of alveolar tissue. H and E stain, X 100.

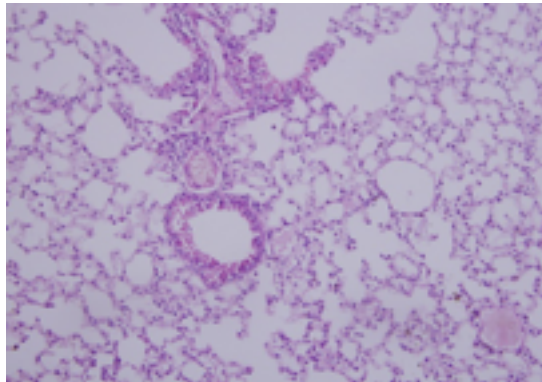


Figure 8. Microscopic view of a lung tissue section obtained from a mouse sacrificed on day 4 following intranasal inoculation with sterile viral transport medium (group 3). The pulmonary tissue looks normal with no evidence of an inflammatory reaction. X 100.

DISCUSSION

The DFA test is a rapid and useful test with high sensitivity and specificity for the diagnosis of HRSV and HMPV infections in children⁽⁹⁻¹¹⁾ and the DFA results obtained during the current study showed that the frequency rates of positive nasopharyngeal swabs are relatively high (24.7% for HRSV and 14.7%

for HMPV), however they are in agreement with the reported incidences of HMPV and HRSV infections among children which range from 1% to 31% and 4% to 41% respectively^(10, 12-18).

The histopathological examination of lung tissue of BALB/c mice intranasally inoculated with HRSV-treated VTM showed an inflammatory response

represented mainly by infiltration of mononuclear inflammatory cells in the perivascular and peribronchiolar areas associated with alveolar tissue distortion and bronchiolar epithelial sloughing. The intensity of this inflammatory response was gradually declined from the 4th to the 10th post-inoculation day reflecting a peak inflammatory response in the 4th post-inoculation day and recovery from infection by the 10th post-inoculation day. This result, which coincides with the general concept that the inflammatory response to viral infections is characteristically composed of mononuclear inflammatory cells⁽¹⁹⁾ is consistent with the findings of Johnson *et al.* (2007)⁽²⁰⁾ and Stokes *et al.* (2011)⁽²¹⁾ who mentioned that the lung histology in cases of HRSV infection showed an inflammatory reaction characterized by lymphocytes and macrophages infiltration. Syncytium formation was observed within the pulmonary epithelial tissue in two out of the nine mice exposed to intranasal inoculation with HRSV-treated VTM. The syncytium is a multinucleated giant cell formed by fusion of viral-infected cells due to function of the viral F protein^(22, 23). This finding is consistent with a similar result of *in vivo* syncytium formation due to HRSV infection in mice experimentally infected with HRSV⁽²⁴⁾ and is also consistent with the results of *in vitro* syncytium formation due to HRSV infection in tissue cultures⁽²⁵⁻²⁷⁾.

One of the mice exposed to intranasal inoculation with HRSV-treated VTM died 4 days post-inoculation and the histopathological examination of its lung tissue showed an intense inflammatory response in the perivascular and peribronchiolar areas in comparison with the other mice which showed a less intense inflammatory reaction. The difference in intensity of inflammatory reaction among mice can be attributed to the difference in individual's genetic makeup among these mice which in turn may affect their immune response⁽²⁸⁾.

Similarly, the histopathological examination of lung tissue of BALB/c mice exposed to intranasal inoculation with HMPV-treated VTM showed an inflammatory response represented mainly by infiltration of mononuclear inflammatory cells in the perivascular and peribronchiolar areas associated with bronchiolar epithelial sloughing, slight deposition of edematous fluid within the interalveolar septa and distortion of alveolar tissue. The peak inflammatory response appeared at the 7th post-inoculation day and recovery from infection occurred at the 10th post-inoculation

day. These results are also in accordance with the general concept that viral infections are associated with infiltration of lymphocytes and macrophages⁽¹⁹⁾ and they are approximately in consistent with the findings of Alvarez *et al.* (2004)⁽⁵⁾ who described a similar mononuclear inflammatory response peaked at the 5th-7th post-inoculation days and declined thereafter.

REFERENCES

1. Gaunt ER, Jansen RR, Poovorawan Y, Templeton KE, Toms GL, Simmonds P. Molecular epidemiology and evolution of human respiratory syncytial virus and human metapneumovirus. *PloS one*. 2011;6:e17427.
2. Li X-y, Chen J-y, Kong M, Su X, Yi Y-p, Zou M, Zhang H. Prevalence of shuman metapneumovirus in hospitalized children with respiratory tract infections in Tianjin, China. *Archives of virology*. 2009;154:1831-1836.
3. Sánchez-Yebra W, Ávila-Carrillo J, Giménez-Sánchez F, Reyes-Bertos A, Sánchez-Forte M, Morales-Torres M, Rojas A, Mendoza J, Group LR. Viral agents causing lower respiratory tract infections in hospitalized children: evaluation of the Speed-Oligo® RSV assay for the detection of respiratory syncytial virus. *European journal of clinical microbiology & infectious diseases*. 2012;31:243-250.
4. Rudan I, Tomaskovic L, Boschi-Pinto C, Campbell H. Global estimate of the incidence of clinical pneumonia among children under five years of age. *Bulletin of the World Health Organization*. 2004;82:895-903.
5. Alvarez R, Harrod KS, Shieh W-J, Zaki S, Tripp RA. Human metapneumovirus persists in BALB/c mice despite the presence of neutralizing antibodies. *Journal of virology*. 2004;78:14003-14011.
6. Domachowske JB, Bonville CA, Rosenberg HF. Animal models for studying respiratory syncytial virus infection and its long term effects on lung function. *The Pediatric infectious disease journal*. 2004;23:S228-S234.
7. Kuiken T, van den Hoogen BG, van Riel DA, Laman JD, van Amerongen G, Sprong L, Fouchier RA, Osterhaus AD. Experimental human metapneumovirus infection of cynomolgus macaques (*Macaca fascicularis*) results in virus replication in ciliated epithelial cells and pneumocytes with associated lesions throughout the respiratory tract. *The American journal of pathology*. 2004;164:1893-1900.
8. Kong X, Hellermann GR, Patton G, Kumar M, Behera A, Randall TS, Zhang J, Lockey RF, Mohapatra SS. An immunocompromised BALB/c mouse model for respiratory syncytial virus infection. *Virology*. 2005;2:3.

9. Landry ML, Ferguson D. SimulFluor respiratory screen for rapid detection of multiple respiratory viruses in clinical specimens by immunofluorescence staining. *Journal of clinical microbiology*. 2000;38:708-711.
10. Ebihara T, Endo R, Ma X, Ishiguro N, Kikuta H. Detection of human metapneumovirus antigens in nasopharyngeal secretions by an immunofluorescent-antibody test. *Journal of clinical microbiology*. 2005;43:1138-1141.
11. Vinh DC, Newby D, Charest H, McDonald J. Evaluation of a commercial direct fluorescent-antibody assay for human metapneumovirus in respiratory specimens. *Journal of clinical microbiology*. 2008;46:1840-1841.
12. Whiley DM, Syrmis MW, Mackay IM, Sloots TP. Detection of human respiratory syncytial virus in respiratory samples by LightCycler reverse transcriptase PCR. *Journal of clinical microbiology*. 2002;40:4418-4422.
13. Falsey AR, Criddle MC, Walsh EE. Detection of respiratory syncytial virus and human metapneumovirus by reverse transcription polymerase chain reaction in adults with and without respiratory illness. *Journal of clinical virology*. 2006;35:46-50.
14. Pabbaraju K, Wong S, McMillan T, Lee BE, Fox JD. Diagnosis and epidemiological studies of human metapneumovirus using real-time PCR. *Journal of Clinical Virology*. 2007;40:186-192.
15. Bellei N, Carraro E, Perosa A, Watanabe A, Arruda E, Granato C. Acute respiratory infection and influenza-like illness viral etiologies in Brazilian adults. *Journal of medical virology*. 2008;80:1824-1827.
16. Heikkinen T, Österback R, Peltola V, Jartti T, Vainionpää R. Human metapneumovirus infections in children. *Emerging infectious diseases*. 2008;14:101.
17. Rafiefard F, Yun Z, Örvell C. Epidemiologic characteristics and seasonal distribution of human metapneumovirus infections in five epidemic seasons in Stockholm, Sweden, 2002–2006. *Journal of medical virology*. 2008;80:1631-1638.
18. Gökalp C, Gökahmetoğlu S, Deniz ES, Güneş T. [Investigation of respiratory syncytial virus by three different methods in children with lower respiratory tract infection]. *Mikrobiyoloji bulteni*. 2009;43:433-438.
19. Griffin DE: The inflammatory response to acute viral infections. In: *Concepts in viral pathogenesis*, Springer; 1984. pp. 46-52.
20. Johnson JE, Gonzales RA, Olson SJ, Wright PF, Graham BS. The histopathology of fatal untreated human respiratory syncytial virus infection. *Modern pathology*. 2007;20:108-119.
21. Stokes KL, Chi MH, Sakamoto K, Newcomb DC, Currier MG, Huckabee MM, Lee S, Goleniewska K, Pretto C, Williams JV. Differential pathogenesis of respiratory syncytial virus clinical isolates in BALB/c mice. *Journal of virology*. 2011;85:5782-5793.
22. Bitko V, Oldenburg A, Garmon NE, Barik S. Profilin is required for viral morphogenesis, syncytium formation, and cell-specific stress fiber induction by respiratory syncytial virus. *BMC microbiology*. 2003;3:9.
23. Ghildyal R, Ho A, Jans DA. Central role of the respiratory syncytial virus matrix protein in infection. *FEMS microbiology reviews*. 2006;30:692-705.
24. Taylor G, Stott E, Hughes M, Collins A. Respiratory syncytial virus infection in mice. *Infection and immunity*. 1984;43:649-655.
25. Gower TL, Pastey MK, Peeples ME, Collins PL, McCurdy LH, Hart TK, Guth A, Johnson TR, Graham BS. RhoA signaling is required for respiratory syncytial virus-induced syncytium formation and filamentous virion morphology. *Journal of virology*. 2005;79:5326-5336.
26. Oomens AG, Bevis KP, Wertz GW. The cytoplasmic tail of the human respiratory syncytial virus F protein plays critical roles in cellular localization of the F protein and infectious progeny production. *Journal of virology*. 2006;80:10465-10477.
27. Mitra R, Baviskar P, Duncan-Decocq RR, Patel D, Oomens AG. The human respiratory syncytial virus matrix protein is required for maturation of viral filaments. *Journal of virology*. 2012;86:4432-4443.
28. De Maio A, Torres MB, Reeves RH. Genetic determinants influencing the response to injury, inflammation, and sepsis. *Shock*. 2005;23:11-17.